



## Passive Straight Leg Raise Test: Definition, Interpretation, Limitations and Utilization

### ABSTRACT

This article highlights the myths and misunderstandings surrounding the straight leg raise (SLR) test for sciatica. Unfortunately, neither intra- nor inter-observer reliability of the passive SLR test has ever been agreed upon. In addition, there is poor consensus about what constitutes a positive SLR test in terms of pain location, leg elevation limitation or clinical significance. Until there are stricter performance standards and uniform agreement, researchers and clinicians should interpret the test with caution. We believe a true positive SLR should be the reproduction or exacerbation of the typical leg dominant pain in the affected limb at any degree of passive elevation. Those with only increased back pain or any leg pain other than that presenting as the chief complaint should be regarded as false positives.

**KEYWORDS:** low back pain, straight leg raise, sciatica, irritative test



CME

Pre-test Quiz



Sciatica is constant leg dominant pain anywhere from the gluteal fold and lower buttock down to the knee, calf or foot.<sup>1</sup> It results from irritation, usually inflammatory, within or adjacent to the spinal canal of one or more of the roots of the nerves that combine to form the sciatic nerve (L4, L5, S1, S2). Charles Lasegue first published the effects of stretching the sciatic nerve by extending the knee with the hip flexed. Lasegue's medical student JJ Forst was the first to describe the more common passive straight leg raise in his medical thesis of 1881.<sup>2</sup> Today, the passive straight leg raise (SLR) is a common component of a low back examination<sup>3,4</sup> and



*Dr. Hamilton Hall, MD, FRCSC, is a Professor in the Department of Surgery at the University of Toronto. He is the Medical Director, CBI Health Group and Executive Director of the Canadian Spine Society in Toronto, Ontario.*



*Greg McIntosh, MSc, completed his Masters in Epidemiology from the University of Toronto's Faculty of Medicine. He is currently the Director of Clinical Research for CBI Health Group and research consultant to the Canadian Spine Society.*



is the test of nerve root irritation most often associated with the designation of sciatica and the concurrent diagnosis of an acute lumbar disc herniation.<sup>5</sup>

While only a few studies have concluded that the passive SLR has high specificity;<sup>6,7</sup> several studies have shown high sensitivity and low specificity<sup>4,8-10</sup> indicating that a negative test is diagnostically more important than a positive one.<sup>11</sup>

The chief diagnostic value of the SLR may be in ruling out the presence of sciatic nerve root irritation. We consider a test that does not reproduce a patient's typical leg dominant pain to indicate there is no irritation of the roots of the sciatic nerve.<sup>1</sup>

Unfortunately, neither intra- nor inter-observer reliability of the passive SLR test has been established.<sup>5</sup> In addition, there is little agreement about what constitutes a positive passive SLR test in terms of pain location, leg elevation limitation or clinical significance.<sup>12</sup> The location of the pain in a positive test has varied from ipsilateral leg pain below the knee, to general leg pain, to a combination of back and leg pain.<sup>1,5,13-16</sup> The reproduction/exacerbation of pain as the examiner lifts the affected leg is generally considered to indicate the presence of root irritation<sup>17</sup> but there is wide variation in the significance attributed to the angle of elevation at which that pain is elicited. Brieg and Troup<sup>18</sup> and oth-

ers<sup>19</sup> have suggested that less than 70 degrees is clinically meaningful. Unfortunately, some clinicians misinterpret pain produced above that level as a negative result. A positive test is one that reproduces a patient's typical leg dominant pain. A clinically meaningful test is one that indicates a level of root irritation requiring treatment. The higher the leg can be lifted before the typical pain is produced, the less irritability that is present. Patients suffering severe sciatica may be unable to even fully extend the knee, much less allow the leg to be lifted. By the time the root irritation has subsided to the point where a patient can tolerate over 70 degrees of elevation, recovery without aggressive medical intervention is almost assured. An SLR test remains positive however, when it produces or increases the typical leg pain regardless of the degree of elevation.<sup>20</sup> From a purely diagnostic perspective, reproduction of leg pain is more important than the degree of limitation.<sup>1,20-22</sup>

A second problem with interpreting the test at elevations above 70 degrees is the appearance of pain from tight hamstrings. When a patient reports pain in the back of the thigh, this is frequently confused with the radicular pain of true sciatica. To significantly reduce this confusion, the SLR can be performed in sitting or, with a patient supine and the contralateral hip



and knee flexed so that the foot is as close to the buttock as possible. Both of these positions rotate the pelvis backward relaxing the hamstring muscles and allowing the straight leg to be lifted about

---

THE TERM SCIATICA, AS IT IS FREQUENTLY EMPLOYED, HAS SEVERAL CHARACTERISTICS THAT ARE EITHER POORLY DOCUMENTED OR SIMPLY ASSUMED TO BE VALID. AS A RESULT THE LINK BETWEEN SLR TESTING AND TRUE SCIATIC PAIN IS SURROUNDED IN CONTROVERSY.

---

an additional 20 degrees without discomfort. The altered starting position does not reduce the sensitivity of the test for nerve root irritation.

Differentiating between root and hamstring pain is a reason that many clinicians employ a variety of secondary tests to confirm the existence of radicular symptoms; a common example is Braggard's test: elevating the affected leg to the point of pain, lowering it 10 degrees to reduce the pain than dorsiflexing the foot to intensify the pain again. The "bowstring sign", where pressure placed in the popliteal fossa, increases the leg pain is another example. In each case, the test will not affect hamstring pain but

will aggravate sciatica. But these secondary tests and additional discomfort that they create are not required when the SLR is correctly interpreted as reproduction or exacerbation of the patient's typical leg dominant symptoms as identified on history and not just any leg pain.

The term sciatica, as it is frequently employed, has several characteristics that are either poorly documented or simply assumed to be valid. As a result the link between SLR testing and true sciatic pain is surrounded in controversy. Conflicting opinions, lack of standardized test methods and divergent interpretations of what constitutes a positive test yield misleading and perplexing results and confounds treatment decisions.<sup>1,2,23-25</sup> The result is a high number of false positives (those who have no sciatic root irritation but who are reported to exhibit a positive straight leg raise).<sup>26</sup>

For example, in a recent study of 2154 patients, clinical outcomes for different presentations of an apparently positive finding on straight leg raising were used to help define true positive test results (increased leg dominant pain with straight leg raising) from false positive ones (increased back pain with straight leg raising). There were three distinct study groups:

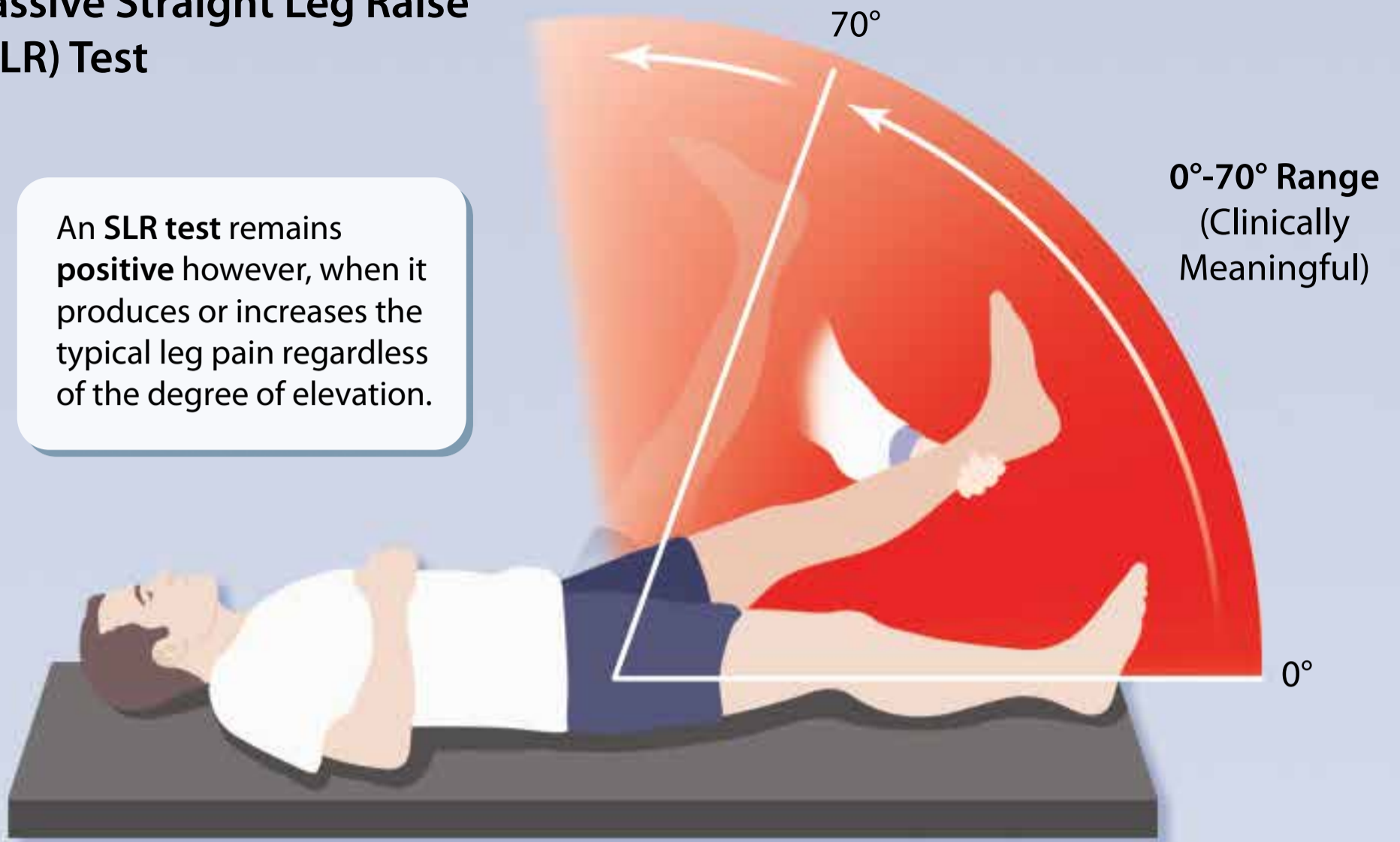
1. positive leg pain: SLR testing



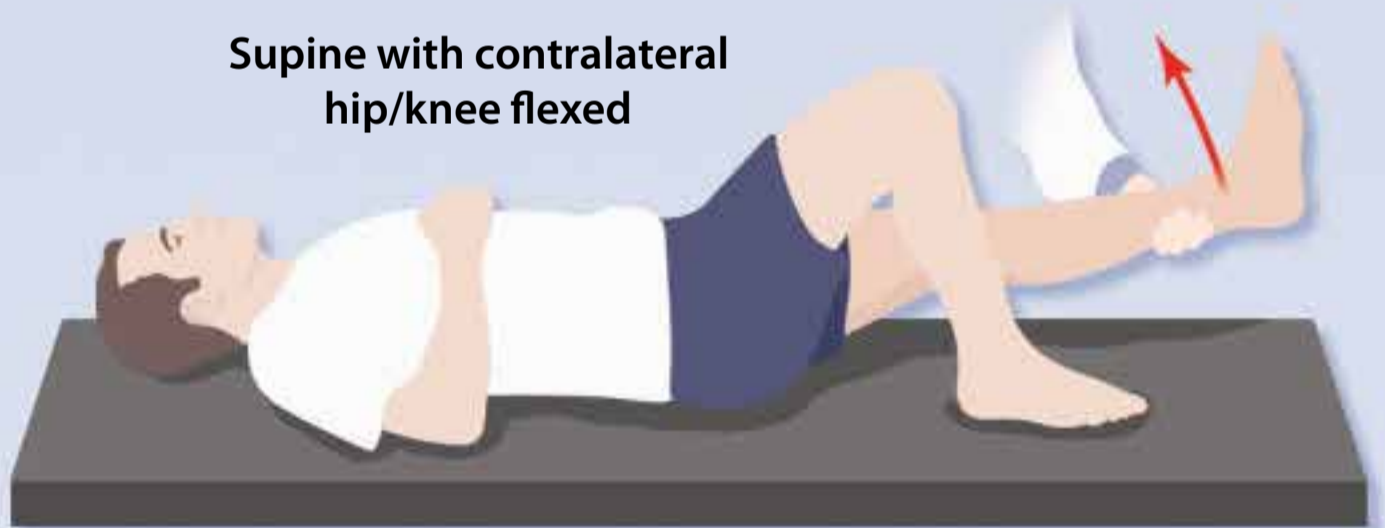


# Passive Straight Leg Raise (SLR) Test

An SLR test remains **positive** however, when it produces or increases the typical leg pain regardless of the degree of elevation.



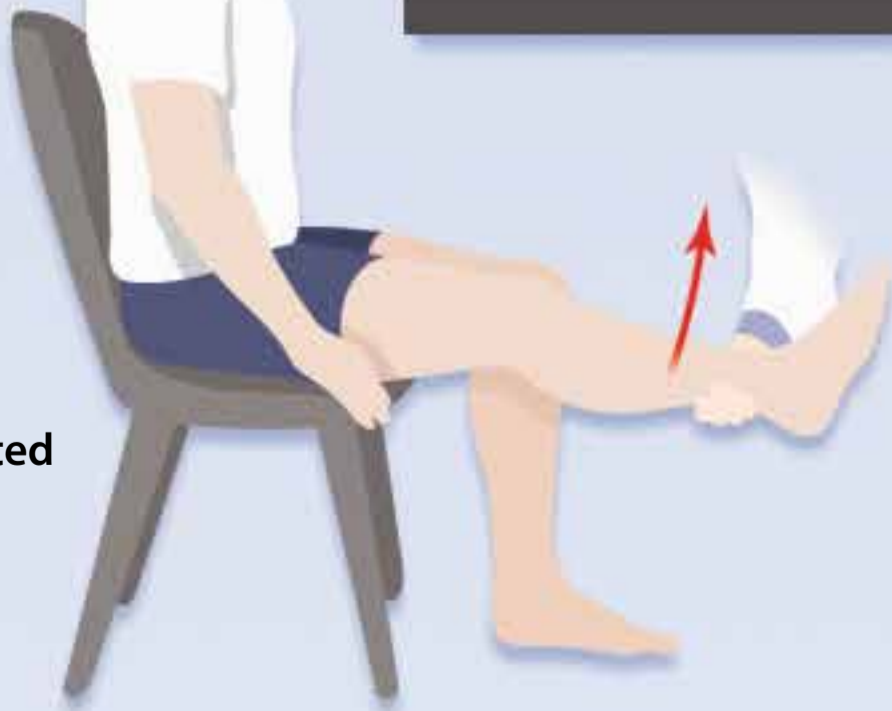
Supine with contralateral hip/knee flexed



## Preferred Positions for the SLR Test

These positions rotate the pelvis and reduce the chance of a "false positive" from painful hamstring tightness.

Seated



- increased the leg dominant pain
- 2. positive back pain: SLR testing increased only the back dominant pain
- 3. no change: no increase in back or leg pain with straight leg raising

---

## A PATIENT WITH A HISTORY OF BACK PAIN ONLY, WITH NO SYMPTOMS BELOW THE BUTTOCKS, WILL NEVER HAVE A TRUE POSITIVE SLR.

---

Given the striking similarity in outcomes between the back pain and no change groups, increased back pain with a passive straight leg raise test should be considered a false positive. The Positive Leg Pain group's outcomes were significantly worse and different from the Positive Back Pain group, offering further evidence that increased back pain on straight leg raising should be considered a false positive.<sup>26</sup>

The proper interpretation of the SLR begins with the history; a step that is frequently overlooked. The leg pain produced or increased with the straight leg lift must be the same pain that a patient described in the history as the worst pain. For the test to be positive, a patient must be suffering radicular symptoms and therefore have a chief complaint of leg dominant pain: pain that is most intense around and/or below the gluteal fold. In

situations where back dominant pain radiates to the leg, the back pain is still reported to be the most painful. Back dominant pain is referred pain without direct nerve root involvement and since the SLR is a test of nerve irritation, the test cannot be positive. It is not pathologically possible to have a patient with a history of back dominant pain and a physical examination showing a positive straight leg raise; there was either an error made in recording the history or performing the examination. To state it even more simply, a patient with a history of back pain only, with no symptoms below the buttocks, will never have a positive SLR. You cannot reproduce radicular pain when a patient has never truly experienced it.

Also essential to an accurate history of true sciatica is determining the presence of constant leg pain.<sup>1,20</sup> The nerve root irritation pain is predominantly inflammatory, not simply mechanical. The intensity of the leg symptoms can vary with position or the degree of root tension but because of the underlying sustained pathology, the pain never completely subsides.

Confirmation during the physical exam means reproduction or exacerbation of the leg dominant pain identified on history. A straight leg raise that causes back pain may be a useful clinical finding for gauging the severity of





## SUMMARY OF KEY POINTS

### Proper passive straight leg raise test technique: Instructions for the clinician.

1. Position the patient supine with the leg to be examined straight out and contralateral knee bent to place the contralateral foot as close as possible to the buttock.
2. Place one hand under the Achilles tendon and the other hand just above the knee.
3. Raise the straight leg slowly noting both the location of the pain and the degree of elevation.
4. A positive test is the reproduction or exacerbation of the patient's leg dominant pain as identified on the history.
5. An increase in back pain is irrelevant.
6. An increase in the typical pain in the leg at any degree of elevation is a positive test indicating nerve root irritation.
7. The SLR should be performed bilaterally.

the mechanical problem but it is a negative test for radicular pain and should be recorded as a negative SLR.<sup>17</sup> A passive SLR test that does not reproduce or exacerbate a patient's typical leg dominant pain indicates no irritation of the roots of the sciatic nerve.<sup>20</sup>

Traditionally, limitation of the SLR was thought to indicate the presence of nerve root compression,<sup>27,28</sup> but there is a poor consensus about the exact cause of pain. Theories include physical pressure on the nerve root itself,<sup>27,28</sup> painful ligamentous structures,<sup>28</sup> involvement of the dural cuff of the nerve,<sup>29</sup> the anterior theca,<sup>17</sup> nerve root edema,<sup>27,30,31</sup> nerve root irritation<sup>32,33</sup> and intervertebral foramen venous obstruction.<sup>34,35</sup> All of them have all been implicated in the literature.<sup>2</sup> But regardless of the putative anatomical cause, a positive SLR test

should be regarded as indicative of direct nerve root involvement, represented by the increase or reproduction of the patient's typical leg dominant pain.

A full discussion of straight leg raising must include two clinical scenarios associated with the test, which are frequently misunderstood: well-leg lift and crossover sign.

Well-leg lift – raising the unaffected leg reproduces the typical pain in the affected leg; this indicates a highly irritable nerve root(s) on the affected side. The patient will frequently be unable even to straighten the painful leg. A positive well-leg lift is a mark of an extremely sensitive root; it identifies severity but not additional pathology.

Crossover sign – raising the straight leg on the affected side



reproduces not only the typical pain in the affected leg but causes pain to radiate into the normally unaffected leg as well. It is bilateral sciatica from a single leg lift. This suggests pathology located in the midline, a central disc herniation, which is a location capable of producing sacral root compression with bowel and bladder compromise: an acute Cauda Equina Syndrome, which is a medical emergency.

Straight leg raising is widely used as a test for sciatica. But until there are stricter performance standards, consensus of interpretation and better attempts at reliability and validity, researchers and clinicians should interpret the test with caution.<sup>36</sup> This review was an attempt to help improve the understanding, utilization, limitations and interpretation of a key diagnostic component of sciatica, the passive straight leg raise (SLR) test. Several key points are worth repeating:

1. the pain of true sciatica is constant,

2. for the test to be positive, a patient must be suffering radicular symptoms and therefore have a chief complaint of leg dominant pain, pain that is most intense around or below the gluteal fold,
3. a positive test is one that reproduces the patient's typical leg dominant pain, not back pain.

### References

1. Hall H. A Consultation with the Back Doctor, Chapter 14. Toronto, Canada: McClelland & Stewart Ltd, 2003.
2. Re bain R, Baxter GD, McDonough S. A systematic review of the passive straight leg raising test as a diagnostic aid for low back pain (1989 to 2000). *Spine* 2002; 27(17): E388-95.
3. Jönsson B, Strömquist B. Neurological signs in lumbar disc herniation. *Acta Orthop Scand* 1996; 67: 466-9
4. Jönsson B, Strömquist B. The straight leg raising test and the severity of symptoms in lumbar disc herniation: a preoperative evaluation. *Spine* 1995; 20: 27-30
5. Kosteljanetz M, Bang F, Schmidt-Olsen S. The clinical significance of straight-leg raising (Lasegue's sign) in the diagnosis of prolapsed lumbar disc. Interobserver variation and correlation with surgical finding. *Spine* 1988; 13(4): 393-5.
6. Capra F, Vanti C, Donati R et al. Validity of the straight-leg raise test for patients with sciatic pain with or without lumbar pain using magnetic resonance imaging results as a reference standard. *J Manipulative Physiol Ther* 2011; 34(4): 231-8.
7. Majlesi J, Togay H, Unalan H et al. The sensitivity and



## CLINICAL PEARLS

1. the pain of true sciatica is constant
2. for the test to be positive, a patient must be suffering radicular symptoms and therefore have a chief complaint of leg dominant pain, pain that is most intense around or below the gluteal fold
3. a positive test is one that reproduces the patient's typical leg dominant pain, not back pain.







CME

## Post-test Quiz

Members of the College of Family Physicians of Canada may claim MAINPRO-M2 Credits for this unaccredited educational program.

- specificity of the Slump and the Straight Leg Raising tests in patients with lumbar disc herniation. *J Clin Rheumatol* 2008; 14(2): 87-91.
8. Poiraudau S, Foltz V, Drape JL et al. Value of the bell test and the hyperextension test for diagnosis in sciatica associated with disc herniation: comparison with Lasegue's sign and the crossed Lasegue's sign. *Rheumatology (Oxford)* 2001; 40(4): 460-6.
  9. Deville WL, van der Windt DA, Dzaferagic A et al. The test of Lasegue: systematic review of the accuracy in diagnosing herniated discs. *Spine* 2000; 25(9): 1140-7.
  10. Vroomen PC, de Krom MC, Knottnerus JA. Diagnostic value of history and physical examination in patients suspected of sciatica due to disc herniation: a systematic review. *J Neurol* 1999; 246(10): 899-906.
  11. Rebain R, Baxter GD, McDonough S. The passive straight leg raising test in the diagnosis and treatment of lumbar disc herniation: a survey of United Kingdom osteopathic opinion and clinical practice. *Spine* 2003; 28(15): 1717-24.
  12. Van den Hoogen H, Koes BW, DeVille W, et al. The inter-observer reproducibility of Lasegue's sign in patients with low back pain in general practice. *Br J Gen Pract* 1996; 46: 727-30.
  13. Jönsson B, Strömquist B. Significance of a persistent positive straight leg raising test after lumbar disc surgery. *J Neurosurg* 1999; 91(1 Suppl): 50-53.
  14. Chow R, Adams R, Herbert R. Straight leg raise test high reliability is not a motor memory artefact. *Aust J Physiother* 1994; 40(2): 107-111.
  15. Turner PG, Green JH, Galasko CSB. Back pain in childhood. *Spine* 1989; 14(8): 812-814.
  16. Thelander U, Fagerlund M, Friberg S, et al. Straight leg raising test versus radiologic size, shape, and position of lumbar disc hernias. *Spine* 1992; 17: 395-9.
  17. Summers B, Malhan K, Cassar-Pullicino V. Low back pain on passive straight leg raising. The anterior theca as a source of pain. *Spine* 2005; 30 (3): 342-5.
  18. Breig A, Troup JD. Biomechanical considerations in the straight-leg-raising test. Cadaveric and clinical studies of the effects of medial hip rotation. *Spine* 1979; 4(3): 242-50.
  19. Xin SQ, Zhang QZ, Fan DH. Significance of the straight-leg-raising test in the diagnosis and clinical evaluation of lower lumbar intervertebral-disc protrusion. *J Bone Joint Surg - A* 1987; 69(4): 517-22.
  20. Lawry GV, Hall H, Ammendolia C et al. The Spine. In Lawry GV, Kreder HJ, Hawker GA, Jerome D, eds. *Fam's Musculoskeletal Examination and Joint Injection Techniques*, second edition. Philadelphia: Mosby Elsevier, 2010: Chapter 8.
  21. Waddell G, Main CJ, Morris EW. Normality and reliability in the clinical assessment of backache. *BMJ* 1982; 284(6328): 1519-1523.
  22. Hall H. Acute Care: Non traumatic Low Back Pain, Chapter 18. In *Orthopaedic Knowledge Update: Spine 2*. AAOS 2002: 153-66
  23. Haldeman S, Shouka M, Robboy S. Computed tomography, electrodiagnostic and clinical findings in chronic workers' compensation patients with back and leg pain. *Spine* 1988; 13(3): 345-50.
  24. van der Windt DA, Simons E, Riphagen II et al. Physical examination for lumbar radiculopathy due to disc herniation in patients with low-back pain. *Cochrane Database Systematic Reviews* 2010; 2:CD007431.
  25. Vroomen PCAJ, De Krom MCTFM, Wilmlink JT et al. Diagnostic value of history and physical examination in patients suspected of lumbosacral nerve root compression. *J Neurol Neurosurg Psychiatry* 2002; 72(5): 630-634.
  26. McIntosh G, Hall H, Carter T. Defining Straight Leg Raise Findings Based on Clinical Outcomes. 2014, unpublished.
  27. Falconer MA, McGeorge M, Begg AC. Observations on the cause and mechanism of symptom-reproduction in sciatica and low-back pain. *J Neurol Neurosurg Psychiatry* 1948; 11: 13-26.
  28. O'Connell JEA. Sciatica and the mechanism of the production of the clinical syndrome in protrusions of the lumbar intervertebral discs. *Br J Surg* 1943; 30: 315-27.
  29. Inman VT, Saunders JB. The clinico-anatomical aspects of the lumbo-sacral region. *Radiology* 1942; 38: 669-78.
  30. Holmes J, Sworn BR. Sciatic neuritis. *BMJ* 1945; 2: 350-1.
  31. Pennybacker J. Sciatica and the intervertebral disc. *Lancet* 1940; 238: 771-7.
  32. Epstein JA, Epstein BS, Rosenthal AD et al. Sciatica caused by nerve root entrapment in the lateral recess: the superior facet syndrome. *J Neurosurg* 1972; 36: 584-9.
  33. Goddard MD, Reid JD. Movements induced by straight leg raising in the lumbo-sacral roots, nerves and plexus, and in the intrapelvic section of the sciatic nerve. *J Neurol Neurosurg Psychiatry* 1965; 28: 12.
  34. Hoyland JA, Freemont AJ, Jayson MIV. Intervertebral foramen venous obstruction, a cause of periradicular fibrosis. *Spine* 1989; 14: 558-68.
  35. Kobayashi S, Yoshizawa H, Hachiya Y, et al. Vasogenic edema induced by compression injury to the spinal nerve root. *Spine* 1993; 18: 1410-24.
  36. Airaksinen O, Brox JI, Cedraschi C, et al. Chapter 4. European guidelines for the management of chronic nonspecific low back pain. *Eur Spine J* 2006; 15 Suppl 2: S192-300.

